

# Multi-Purpose Attachment for Direct-Bonded Lingual Retainers

NIKHIL VASHI, MDS  
BHUMA VASHI, MDS

**W**e have developed a bonded Multi-Purpose Attachment<sup>1</sup> (MPA)\* that we find useful for bonding lingual retainer wires. The MPA, shaped like the letter “P” in its profile view, is only .4mm thick at the base and 1mm thick at the lumen (Fig. 1). Because of its extremely low profile, it is comfortable for the patient and versatile in many lingual and labial applications.




Fig. 1 Thickness of MPA (right) compared to standard brackets.

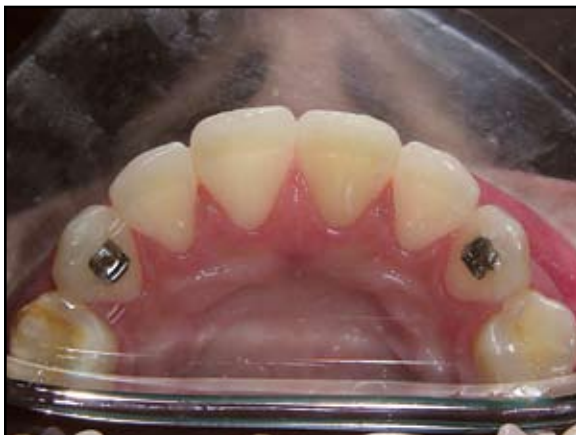

Fig. 2 MPAs bonded to canines with lumens on gingival sides.

## Bonding Procedure

1. Prepare the lingual surfaces of the anterior teeth for bonding in the usual fashion. After applying the bonding agent, place a Multi-Purpose Attachment (MPA) on each canine in the desired position, with the lumen on the gingival (Fig. 2). In the upper arch, the MPA should be placed at an appropriate height to avoid occluding with the lower canines.
2. Pass a twisted wire through the lumens of both attachments (Fig. 3), and adapt the wire passively to the lingual surfaces of the incisors.
3. Cut the excess wire, leaving 2-3mm extending from the distal end of each MPA (Fig. 4).
4. Bond the wire to the teeth with a flowable adhesive (we use Estelite Flow Quick\*\*), so that no polishing is required.<sup>2</sup>
5. Bend the protruding distal ends of the retainer wire gingivally (Fig. 5A), and apply more flowable adhesive to prevent the wire from sliding out of

\*Braces Ideas, 2/13, Madhav Nagar, S.V. Road, Andheri (West), Mumbai 400058, India; www.bracesideas.com. Distributed in the United States by MEMES Associates Ltd., 1632 Charlotte Circle, Naperville, IL 60564.

\*\*Tokuyama America Inc., 740 Garden View Court, Suite 200, Encinitas, CA 92024; www.tokuyama-us.com.

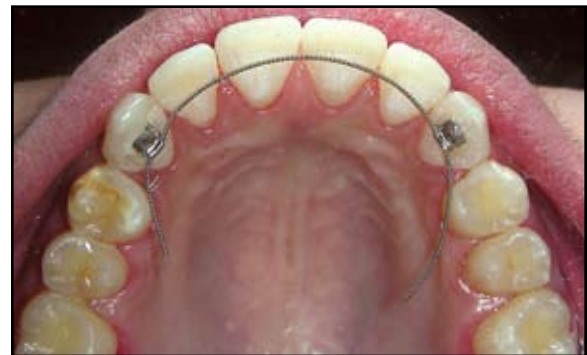

Fig. 3 Retainer wire passed through both MPAs.

Drs. Nikhil Vashi and Bhuma Vashi are in the private practice of orthodontics at 2/13, Madhav Nagar, S.V. Road, Andheri (West), Mumbai 400058, India; e-mail: info@bracesindia.com. The authors have a financial interest in the MPA.



Dr. Nikhil Vashi



Dr. Bhuma Vashi

the tubes and potentially causing relapse. The retainer can be extended to the premolars if necessary to prevent first-premolar extraction spaces from reopening (Fig. 5B).

### Discussion

This method is quick and simple, requiring no floss, ligature wires, or other stabilization to keep the retainer wire from moving during the bonding process. Attachments can easily be bonded at the desired heights, with vertical adjustments made to accommodate the patient's occlusion. Chairtime is shorter, and bond failures are minimal compared to other techniques.

The MPA is useful in many clinical situations where it may be difficult to bond a bracket or tube to avoid patient discomfort from occlusal interference or trauma to the oral tissues. The attachment comes with a flat or curved base and can be bonded with the lumen either to the gingival or the occlusal, depending on the situation. We have used the MPA in cases of severe crowding, rotations, deep bite, crossbite, scissor bite, and impacted and tipped second molars, and for bond-

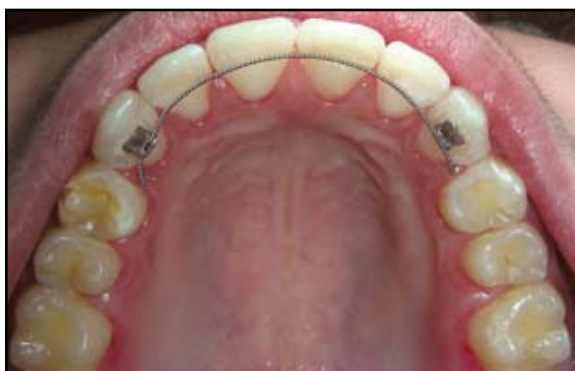
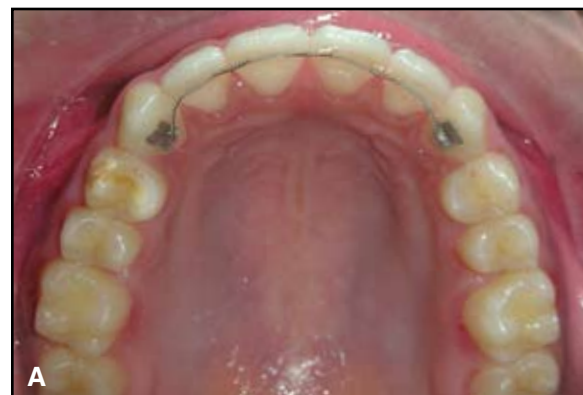
Fig. 4 Retainer wire passively adapted to incisors and cut distal to canines.

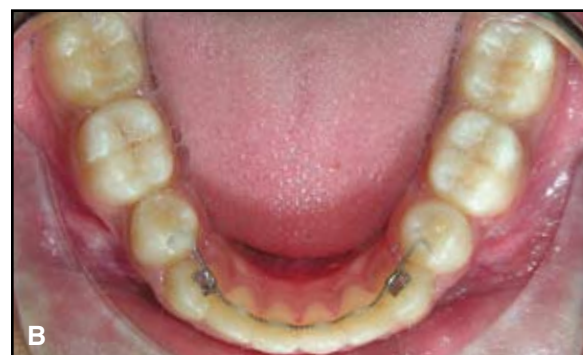ing to surgically exposed teeth, peg laterals, and the occlusal surfaces of partially erupted teeth. The MPA can also be employed as a conventional labial or lingual appliance that provides two-dimensional control.<sup>1</sup>

### REFERENCES

1. Vashi, N.S. and Vashi, B.N.: A multipurpose attachment (MPA), *J. Ind. Orthod. Soc.* 35:89-93, 2002.
2. Elaut, J.; Asscherickx, K.; Vande Vannet, B.; and Wehrbein, H.: Flowable composites for bonding lingual retainers, *J. Clin. Orthod.* 36:597-598, 2002.



A



B

Fig. 5 A. Upper retainer wire ends bent gingivally and bonded to canine surfaces. B. Lower retainer wire extended to premolar surfaces and bonded to prevent reopening of extraction spaces.